

## **Totally laparoscopic right colectomy with transvaginal specimen extraction: the authors' initial institutional experience**

Weill Cornell Medicine is an academic medical center that provides exemplary care for our patients. Our Division of Colon and Rectal Surgery includes the nation's leading surgeons for colon and rectal surgical treatments.

Above and beyond caring for patients, our compassionate physicians and surgeons also conduct research to advance medical understanding, treatments and standards. Notable research is written, reviewed by peer physicians, published and shared with physicians around the world.

Dr. Alessio Pigazzi was appointed the chief of Colon and Rectal Surgery at Weill Cornell Medical Center/NewYork-Presbyterian in 2020. His research focuses on minimally invasive techniques to improve recovery after cancer surgery, postoperative chemotherapy, as well as the relationship between diet and colorectal cancer.

In this article, Dr. Pigazzi and three co-authors present the results of performing a totally laparoscopic right colectomy with transvaginal specimen extraction for surgically treating four patients' cancer.

A right colectomy is a procedure to remove part of the right colon. When performed laparoscopically, the surgeon uses long, thin tubes that are inserted into small incisions (cuts). Transvaginal specimen extraction is the removal of cancerous cells through the vagina ("transvaginal").

The collective results show that totally laparoscopic colectomy with transvaginal extraction is both safe for the patient and feasible for the surgeon to perform. Since it is a minimally invasive technique, there is less danger of abdominal wall bleeding.

## Totally laparoscopic right colectomy with transvaginal specimen extraction: the authors' initial institutional experience

Shaun McKenzie · Jeong-Heum Baek ·  
Mark Wakabayashi · Julio Garcia-Aguilar ·  
Alessio Pigazzi

Received: 14 April 2009 / Accepted: 16 July 2009 / Published online: 28 January 2010  
© Springer Science+Business Media, LLC 2010

### Abstract

**Background** The persistence of early and delayed wound complications related to both open and laparoscopic colectomy remains a significant health burden. Furthermore, as interest in natural orifice transluminal endosurgery (NOTES) continues to grow, bridging techniques may help to attenuate the learning curve associated with NOTES. The authors present their technique and short-term outcomes for totally laparoscopic right colectomy with transvaginal specimen extraction in a series of four patients.

**Methods** Four consecutive patients from a prospectively maintained laparoscopic colectomy database were analyzed under an institutional review board-approved protocol. Clinicopathologic characteristics and short-term outcomes were reviewed.

**Results** All the patients were women with no prior pelvic surgery. A four-trocar laparoscopic right colectomy with intracorporeal anastomosis was performed for cancer in two cases and for adenomatous polyp in two cases. Transvaginal extraction was possible in all cases. The average operating room time was 212.25 min. No patient experienced complications associated with the colpotomy; nor did any patient have pain or drainage from the extraction site postoperatively. The median hospital stay was 4.5 days. One patient experienced a bowel obstruction unrelated to the extraction

site. The mean specimen length was 27 cm, and the mean number of lymph nodes retrieved was 15.75.

**Conclusion** Totally laparoscopic right colectomy with transvaginal extraction appears to be safe and feasible. This technique may provide both an attractive way to reduce abdominal wall morbidity and a bridge to NOTES colon surgery.

**Keywords** Laparoscopic colectomy ·  
Natural orifice transluminal endosurgery (NOTES) ·  
Totally laparoscopic right colectomy ·  
Transvaginal specimen extraction

The development of natural orifice transluminal endoscopic surgery (NOTES) appears to be the next major frontier in minimally invasive surgery. Nevertheless, numerous technical, visual, and safety issues need to be overcome before widespread acceptance of these techniques occurs [1, 2]. As a bridge to NOTES, natural orifice specimen extraction (NOSE) has been proposed, in which the procedure is performed using conventional laparoscopic techniques, with avoidance of an extraction mini-laparotomy. The NOSE technique is appealing in terms of maximizing the benefits of minimal access procedures and progressing toward scarless surgery without the need for drastically novel laparoendoscopic approaches [3].

Laparoscopically assisted colectomy (LAC) for cancer is a technique equivalent to open resection in terms of safety and oncologic outcomes. In addition, LAC has clear advantages with regard to length of hospital stay, narcotic requirement, and return to work [4, 5]. However, surgical wound complications such as infection and postoperative hernia continue to be substantial after both open and laparoscopic colon surgery [6, 7]. Moreover, the

S. McKenzie (✉) · M. Wakabayashi · J. Garcia-Aguilar ·  
A. Pigazzi  
Department of General and Oncologic Surgery,  
City of Hope National Medical Center, 1500 East Duarte Road,  
Duarte, CA 91010-3000, USA  
e-mail: smckenzie@coh.org

J.-H. Baek  
Department of Surgery, Gachon University of Medicine  
and Science, Incheon, Korea

minilaparotomy is likely to be the most important source of postoperative pain after LAC. Avoidance of abdominal wall extraction sites may be desirable to improve the short term benefits of LAC and limit the high cost of wound complication management [8]. Vaginal specimen extraction has been widely used in gynecologic practice with minimal morbidity [9–13]. Nevertheless, experience using NOSE after laparoscopic colectomy is extremely limited, with only eight cases reported in the literature [3, 14].

We describe our technique and results after totally laparoscopic right colectomy with intracorporeal anastomosis and transvaginal specimen extraction in a series of four consecutive cases.

## Methods

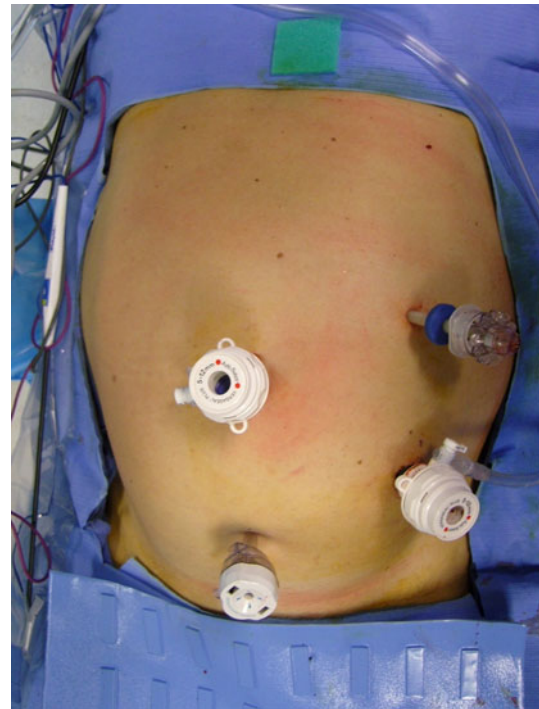
Four consecutive patients were retrospectively reviewed from a prospective database of minimally invasive colon resections. A transvaginal extraction was offered to patients according to criteria specifying female gender, clinically staged T3 or fewer primary tumors, and lack of previous pelvic surgery. All patients provided complete informed consent regarding the addition of transvaginal extraction. The study was performed under institutional review board approval.

## Technique

The patient is positioned in a modified lithotomy position with arms secured at the sides. The abdomen is insufflated to 12–15 mmHg using a left upper-quadrant Veress technique. Four ports are used. The 12-mm camera port is placed at the midpoint between the xyphoid and the pubis through the linea alba. The surgeon's operating ports include a 12-mm working port equidistant from the camera port and the left anterior superior iliac spine and a 5-mm port in the suprapubic location. A final 5-mm assistant port is placed a hand's length superior to the other 5-mm port. This arrangement allows predictable triangulation of the ileocolic pedicle (Fig. 1).

Next, the patient is positioned in the 15° to 30° Trendelenburg and slightly left lateral decubitus position. After the omentum is retracted above the transverse colon and the small intestine is retracted toward the left, the ileocolic pedicle is identified by inferolateral retraction of the ileal fold of Treves. The pedicle is skeletonized at its origin and controlled with a vascular stapler. The right mesocolon is mobilized off the retroperitoneum in a medial to lateral fashion. The duodenum is identified and swept posteriorly, and the right branch of the middle colic artery and vein are controlled with a vessel-sealing device or clips.

The proximal transverse colon then is retracted caudally, and the gastrocolic ligament is opened. The remainder of

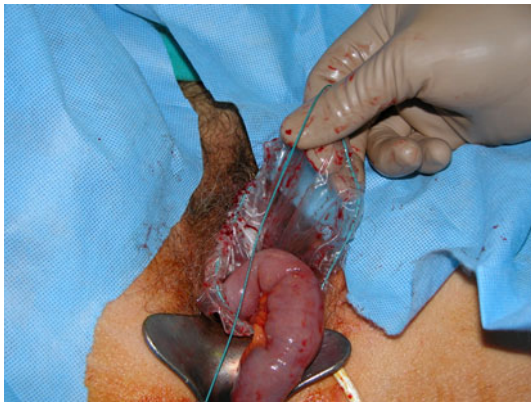


**Fig. 1** Port placement for totally laparoscopic right colectomy

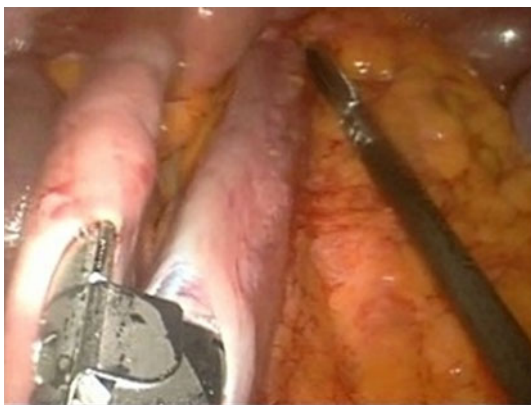
the right colon and terminal ileal mobilization proceeds along the lateral attachments and then along the root of the mesentery. The proximal transverse colon and terminal ileum are transected with gastrointestinal stapling devices, and the specimen is placed in a large retrieval bag.

While the assistant retracts the uterus anterior and places the specimen within the pelvis, the surgeon prepares for extraction. A weighted retractor is used within the vagina to aid with visualization. The cervix is grasped with a tenaculum, and a posterior colpotomy is performed with scissors, cautery, or insertion of a long 12-mm trocar. This procedure is performed under laparoscopic vision to avoid a rectal injury. The string of the specimen bag is grasped with a ring forceps, and the bag is passed transvaginally. By application of constant gentle traction on the retrieval bag cable, the specimen is delivered through the vagina (Fig. 2). The colpotomy then is closed with interrupted absorbable suture extracorporeally. The repair is clearly visualized laparoscopically.

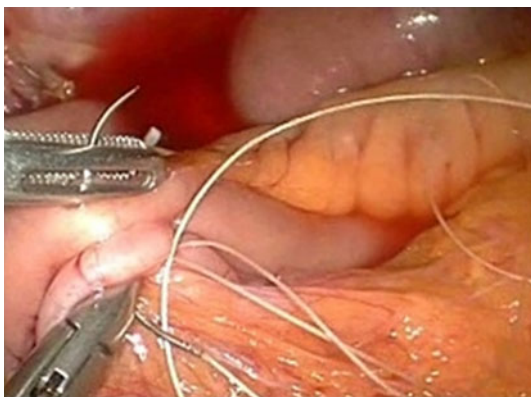
Next, the ileal limb and the transverse colon are aligned in an isoperistalsic fashion with the assistance of a stay suture placed intracorporeally. Paired enterotomies are made with cautery, and a 60-mm stapled side-to-side anastomosis is created (Fig. 3). The remaining enterotomy is closed in two layers with a running intracorporeal suture (Fig. 4). The procedure then is completed in the standard laparoscopic fashion.



**Fig. 2** Transvaginal extraction of the resected specimen after right colectomy



**Fig. 3** Creation of isoperistaltic, ileocolonic anastomosis



**Fig. 4** Closure of enteroenterostomy

## Results

All our patients were elderly women with an intact uterus and no significant prior abdominal or pelvic surgery. No patient experienced complications associated with the extraction site. None reported perineal pain, and none

**Table 1** Patient characteristics and outcomes for four totally laparoscopic right colectomies with transvaginal specimen extraction

	Patient 1	Patient 2	Patient 3	Patient 4
Age (years)	68	73	81	77
BMI	31.1	22.1	24.8	19.8
Comorbidities	None	COPD	CAD	HTN
Blood loss (ml)	30	75	50	50
OR time (min)	263	191	239	156
Complications	None	SBO, abscess	None	Nausea
Postoperative discharge day	4	34	3	5

*BMI* body mass index, *COPD* chronic obstructive pulmonary disease, *CAD* coronary artery disease, *HTN* hypertension, *OR* operating room, *SBO* small bowel obstruction

experienced postoperative vaginal drainage or bleeding. There were no conversions or need to abort a transvaginal extraction site. The median length of hospital stay was 4.5 days. One patient experienced an internal hernia unrelated to either the intracorporeal anastomosis or the transvaginal extraction and required relaparotomy 20 days after surgery and a prolonged hospital stay (Table 1).

The mean operative time for the entire procedure was 212.25 min. For comparison, we identified four women with a similar body mass index (BMI) who underwent laparoscopic right colectomy with intracorporeal anastomosis and extraction through a Pfannenstiel incision. The mean operative time in that cohort with a mean BMI of 25.5 was 212.75 min.

Pathologic analyses of the specimens showed adequate lymph node counts and margins in all four cases (Table 2; Fig. 5).

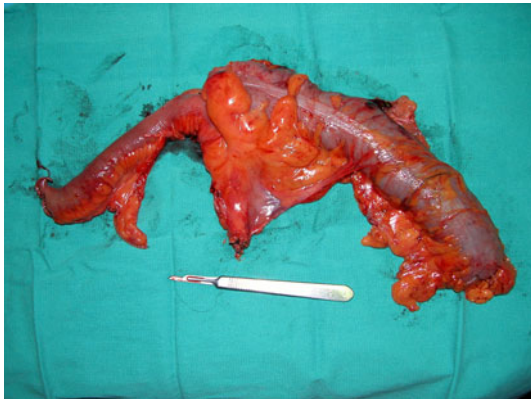## Discussion

Ample level 1 data now exist to support laparoscopic colon resection for malignant disease as a surgical option equivalent to open surgery in terms of perioperative morbidity, mortality, and long-term recurrence and survival [4]. However, improvements in wound complications with LAC have not been reported consistently in the literature. In a prospective randomized trial comparing wound complications between open and laparoscopic colon resections, Winslow et al. [6] found no statistically significant difference in the superficial wound infection or postoperative hernia rates between the two treatment arms of their study. In particular, complications at the specimen extraction site accounted for the vast majority of laparoscopic wound complications.

Similar studies focused on perioperative outcomes related to the surgical wound have confirmed that the rate

**Table 2** Pathologic characteristics

Diagnosis	Patient 1 Tubulovillous adenoma	Patient 2 Adenocarcinoma	Patient 3 Adenomatous polyp with high-grade dysplasia	Patient 4 Adenocarcinoma
Tumor size (cm)	1.9	3.2	1	4.2
Specimen length (cm)	22.4	52.5	15	18
No. of lymph node retrieved	16	13	22	12
Stage	T0N0	T3N1	T0N0	T3N0

**Fig. 5** Resected specimen after transvaginal extraction

of hernia, both asymptomatic and symptomatic, is similar between open and laparoscopic colon resections, especially if a midline extraction site is used [7, 8]. The health care costs of wound-related complications remain significant [15], requiring improvements in surgical technique that limit wound complications and improve postoperative outcomes.

In 2007, Palanivelu et al. [3] presented their series of seven patients with familial adenomatous polyposis who underwent totally laparoscopic proctocolectomy with specimen extraction through a posterior colpotomy. They identified no complications and described complete healing of the extraction site by the initial follow-up assessment. Therefore, they proposed that NOSE may eliminate the local wound complications associated with transabdominal colonic specimen retrieval.

Franklin et al. [14] provided the first case report of totally laparoscopic right colectomy with intracorporeal anastomosis and specimen extraction through a posterior colpotomy. Again, their patient experienced no complications associated with the performance of an intracorporeal anastomosis and no morbidity associated with the vaginal extraction site.

Our technique varies from that of Franklin et al. [14] somewhat in that the anastomosis is created in an isoperistaltic fashion, and the enterotomy is closed with sutures rather than stapled. Although we prefer a laparoscopic

suture closure of this enterotomy, a double-stapling technique or a robotically assisted closure is an acceptable option for anastomotic creation.

The precedent for vaginal specimen extraction has been well established in the gynecologic literature. For patients with ovarian, endometrial, or cervical cancer, laparoscopic resection and surgical staging have been performed using vaginal specimen extraction with no compromise of oncologic or functional outcomes [11–13]. Moreover, the rate of dyspareunia is not reported to be significant after posterior colpotomy and specimen retrieval [9, 10].

In colorectal cancer, early concerns of port- and extraction-site recurrences after laparoscopic resection have been proved unfounded in many recent analyses [4]. Therefore, as long as proper oncologic principles and specimen handling are respected, the risk of pelvic tumor seeding during transvaginal delivery should be no higher than with transabdominal extraction.

In our series of patients, we used a specimen retrieval bag to provide wound protection during extraction, avoiding any contact between the tumor-bearing colon and the pelvic or perineal structures. We report the largest series to date of totally laparoscopic right colectomy with intracorporeal anastomosis and transvaginal specimen extraction. None of our four patients experienced complications related to the creation of an intracorporeal anastomosis or the transvaginal extraction site. Nor did the transvaginal extraction add to our operative times. The safety, efficacy, and feasibility of an intracorporeal anastomosis in this setting have been established [16, 17].

Posterior colpotomy, an avenue for specimen extraction of gynecologic masses since it was first described in 1896, appears to be one of the preferred routes of access in the early development of NOTES [1, 2, 9–13, 18]. Our one complication in this small series occurred due to a bowel obstruction secondary to an internal hernia through the remaining mesenteric defect. It is our standard practice to leave the mesenteric defect open after laparoscopic right colectomy regardless of anastomotic technique or extraction site, and we have not seen this complication previously in more than 200 cases in our database. We do not think this complication was related to the new approach.

We believe that totally laparoscopic colon resection with intracorporeal anastomosis and transvaginal specimen extraction is feasible, safe, and oncologically acceptable for selected cases. For patients who are not candidates for transvaginal extraction, we continue to recommend intracorporeal anastomosis with Pfannenstiel-site extraction as an alternative to extracorporeal anastomosis.

Ideal patients for transvaginal colon extraction should have an intact uterus to act as a natural barrier between the bladder and the vagina and should have undergone no other pelvic surgery that may have resulted in adhesions between the rectum and the vagina. In addition, we believe transvaginal extraction of bulky specimens is unwarranted. Further prospective investigations are needed to assess better the long-term impact of this technique with respect to quality of life and cost effectiveness.

As the role of NOTES continues to be defined in surgical practice, we believe that NOSE can provide a bridge to this emerging technology, perhaps lessening part of the learning curve associated with the adoption of these new techniques.

## Conclusion

Totally laparoscopic right colectomy with intracorporeal anastomosis and transvaginal extraction appears to be feasible and safe for selected patients with colorectal neoplasia. Further studies are necessary to establish this technique as an accepted option in the laparoscopic management of colorectal malignancy.

**Disclosures** Shaun McKenzie, Jeong Heum-Baek, Mark Wakabayashi, Julio Garcia-Aguilar, and Alessio Pigazzi have no conflicts of interest or financial relationships to disclose.

## References

1. Al-Akash M et al (2009) NOTES: The progression of a novel and emerging technique. *Surg Oncol* 18:95–103

2. Al-Akash M et al (2009) Training on NOTES: from history we learn. *Surg Oncol* 18:111–119
3. Palanivelu C et al (2008) An innovative technique for colorectal specimen retrieval: a new era of “natural orifice specimen extraction” (NOSE). *Dis Colon Rectum* 51:1120–1124
4. Kuhry E, Schwenk W et al (2009) Long-term results of laparoscopic colorectal cancer resection. *Cochrane Database Syst Rev* 1:1–61
5. Tjandra J, Chan M (2006) Systematic review of the short-term outcomes of laparoscopic resection for colon and rectosigmoid cancer. *Colorectal Dis* 8:375–388
6. Winslow ER, Fleshman JW et al (2002) Wound complications of laparoscopic versus open colectomy. *Surg Endosc* 16:1420–1425
7. Ihediohau U, Mackay G et al (2008) Laparoscopic colorectal resection does not reduce incisional hernia rates when compared to open colorectal resection. *Surg Endosc* 22:689–692
8. Singh R, Omiccioli A et al (2008) Does the extraction-site location in laparoscopic colorectal surgery have an impact on incisional hernia rates? *Surg Endosc* 22:2596–2600
9. Ghezzi F, Raio L et al (2002) Vaginal extraction of pelvic masses following operative laparoscopy. *Surg Endosc* 16:1691–1696
10. Yoong W, Pillai R (2009) Posterior colpotomy: a retrieval route for solid ovarian malignancies. *BJOG: An International Journal of Obstetrics and Gynaecology* 465–466
11. Malzoni M, Tinelli R et al (2009) Total laparoscopic radical hysterectomy versus abdominal radical hysterectomy with lymphadenectomy in patients with early cervical cancer. *Ann Surg Oncol* 16:1316–1323
12. Wong C, Wong Y et al (2005) Laparoscopy compared with laparotomy for the surgical staging of endometrial carcinoma. *J Obstet Gynecol Res* 31:286–290
13. Jung Y, Lee J et al (2009) Feasibility and efficacy of laparoscopic management of ovarian cancer. *J Obstet Gyn Res* 35:113–118
14. Franklin ME, Kelley H et al (2008) Transvaginal extraction of the specimen after total laparoscopic right colectomy with intracorporeal anastomosis. *Surg Laparosc Endosc Percut Tech* 18:294–298
15. Graves N, Halton K et al (2008) Who bears the cost of health care-acquired surgical-site infection. *J Hosp Infect* 69:274–282
16. Bergamaschi R, Schochet E et al (2008) Standardized laparoscopic intracorporeal right colectomy for cancer: short-term outcome in 111 unselected patients. *Dis Colon Rectum* 51:1350–1355
17. Raftopoulos I, Courcoulas A et al (2006) Should completely intracorporeal anastomosis be considered in obese patients who undergo laparoscopic colectomy for benign and malignant disease of the colon. *Surgery* 140:675–682
18. Forgione A, Maggioni D et al (2008) Transvaginal endoscopic cholecystectomy in human beings: preliminary results. *J Laparosc Adv Surg Tech* 18:345–351